

Clinical Surgery-American

Negative preoperative localization leads to greater resource use in the era of minimally invasive parathyroidectomy

Avital Harari, M.D., John Allendorf, M.D., Alexander Shifrin, M.D.,
Mary DiGorgi, M.S., M.P.H., William B. Inabnet, M.D.*

Division of Gastrointestinal and Endocrine Surgery, Department of Surgery, 161 Fort Washington Ave., College of Physicians and Surgeons of Columbia University, New York, NY 10032, USA

KEYWORDS:

Primary
hyperparathyroidism;
Negative imaging;
Cost;
Minimally invasive
parathyroidectomy

Abstract

BACKGROUND: Successful preoperative localization plays an important role in patient selection for focused parathyroidectomy.

METHODS: The case records of 499 consecutive patients with presumed hyperparathyroidism who underwent neck exploration were reviewed. Positive imaging patients ($n = 373$) had a localizing study that clearly showed a single abnormal parathyroid gland whereas negative imaging patients ($n = 44$) failed to localize or had discordant imaging results.

RESULTS: Positive imaging patients were more likely to have a single adenoma (93.0% vs 72.1%; $P < .001$), and were less likely to require a bilateral exploration (8.1% vs 70.4%; $P < .001$). Negative imaging patients required more frozen sections ($.9 \pm 1.3$ vs $.2 \pm .7$; $P < .001$), and longer surgical time (77.3 ± 52.5 min vs 48.4 ± 34.6 min; $P < .001$). The cure rate was significantly higher in the positive imaging group (96.0% vs 87.1%; $P < .03$), with no difference in the incidence of complications (3.2% vs 2.3%; P value was not significant).

CONCLUSIONS: Patients with unsuccessful or discordant preoperative localization have a higher incidence of multigland disease, lower cure rate, and consume more institutional resources than patients with successful preoperative localization.

© 2009 Elsevier Inc. All rights reserved.

Primary hyperparathyroidism (PHPT) is relatively common in the general population with an incidence estimated at 1 or more per 1,000.¹ The prevalence of PHPT has been reported to be as high as 4 per 1,000.¹⁻³ Causes of PHPT include parathyroid adenoma, double adenoma, 3- or

4-gland hyperplasia, and, rarely, parathyroid cancer.² In the era of focused parathyroid surgery, the prevalence of a solitary adenoma being the cause of PHPT ranges from 80% to 95%.^{2,4-9}

The treatment goal for patients with PHPT is surgical excision of an adequate amount of hyperfunctioning parathyroid tissue to render the patient eucalcemic after surgery.¹ Although bilateral neck exploration has been considered the treatment of choice in patients with PHPT (and still is advocated by some groups), several surgical techniques of limited neck exploration have been proposed for treating PHPT.¹⁰⁻¹² Successful preoperative localization plays an

Presented at the New York Surgical Society Meeting, February 7, 2007, New York, NY.

* Corresponding author. Tel.: +1-212-305-0444; fax: +1-212-305-0445.

E-mail address: wbi2102@columbia.edu

Manuscript received February 9, 2008; revised manuscript April 23, 2008

important role in patient selection for targeted parathyroid surgery. Improvements in parathyroid imaging techniques, the availability of surgical adjuncts that permit intraoperative assessment of parathyroid gland activity (ie, intraoperative PTH assay and radioguidance), and the ever-increasing acceptance of minimally invasive procedures have contributed to a philosophic change in the surgical management of PHPT.^{1,5,7,13}

A National Institutes of Health statement in 1991 deemed preoperative parathyroid localization unnecessary and rarely indicated because an experienced endocrine surgeon will successfully locate enlarged parathyroid gland(s) at surgery in up to 95% of cases.^{1,5,13-15} A 2002 revision of the 1991 consensus statement warmed up to the utility of parathyroid localization yet fell short of fully embracing preoperative parathyroid imaging studies.¹⁶ Thus, the use of preoperative imaging for first-time parathyroid exploration remains controversial, especially in the setting of cost-conscious health care management.⁹

Significant improvements in parathyroid scintigraphic techniques such as technetium-99m sestamibi dual-phase scanning (MIDI) and single photon emission computed tomographic scintigraphy (SPECT) have helped achieve a specificity of 91% and a sensitivity of 98.8% for detecting parathyroid pathology.^{1,2} When preoperative sestamibi scanning is used in conjunction with intraoperative parathyroid hormone monitoring, the positive predictive value for surgical cure of PHPT ranges from 96% to 100%.^{1,13}

At an estimated cost of \$550 per scan, one study concluded that Tc-99m-sestamibi scanning is not warranted before initial surgery for PHPT.¹⁷ It is well known that the quality of sestamibi scanning is highly variable because the technique varies from institution to institution. In a 2002 study, sestamibi SPECT correctly lateralized 349 of 400 abnormal parathyroid glands, with an overall sensitivity of only 87%, an accuracy of 94%, and a positive predictive value of 86%.¹⁸ Another study showed that MIBI scans correctly localized only 80% of involved glands.⁷ Thus, up to 20% of people could have negative or incorrect sestamibi scans going into a surgery, in which case further preoperative and intraoperative work-up may be indicated to determine the etiology of PHPT.^{2,7,19} In this study we compared the outcomes of patients with positive and negative preoperative localization to determine the impact of successful localization on resource use and cure rate.

Methods

Permission was obtained from the Institutional Review Board of Columbia University to conduct a retrospective review of the Division of Gastrointestinal and Endocrine Surgery's Parathyroid Registry. Because of the retrospective nature of the study, the need for informed consent was waived. Data were exported from the Parathyroid Registry in a de-identified manner so that patient confidentiality was maintained.

The case records of 499 consecutive patients who underwent neck exploration for presumed PHPT from June 1998 through August 2005 were reviewed retrospectively. Patients with familial hyperparathyroidism, secondary and tertiary hyperparathyroidism, and those explored for recurrent or persistent disease were excluded from the analysis. Ultimately, 417 of 499 patients with PHPT met criteria for inclusion in the study group. All patients underwent 1 or more preoperative localizing studies including sestamibi scanning, ultrasound, and/or computed tomography. Patients were stratified into 1 of 2 groups. Positive imaging patients ($n = 373$; 89.5%) were defined as patients who had a solitary parathyroid adenoma visualized on preoperative imaging and in whom a focused parathyroid surgery was planned. Negative imaging patients ($n = 44$; 10.5%) were defined as patients who met one of the following criteria: no evidence of abnormal parathyroid tissue, discordant or conflicting findings on 2 or more studies, or findings suggestive of multigland disease. Regarding sestamibi scanning, positive sestamibi scans from outside institutions (as interpreted by the surgeon) also were included in the study. If an outside scan showed a solitary area of increased uptake (ie, a solitary adenoma), the scan was not repeated; if the study was negative or equivocal, it was repeated at the surgeons' institution if all other localizing studies were negative.

Outcomes that were compared included age, sex, preoperative and postoperative laboratory results, type of surgical approach (unilateral vs bilateral), type of anesthesia, surgical time, pathology, complication rate, and duration of hospital stay. For procedures performed under local anesthesia, a combined deep and superficial cervical block was performed on the side of the neck of the planned exploration along with a contralateral superficial cervical block. For patients undergoing bilateral neck exploration, a bilateral deep and superficial cervical block was performed.

Intraoperative parathyroid hormone (PTH) assay and radioguidance monitoring was used in all patients with intraoperative success being defined as a greater than 50% reduction from the highest pre-excision PTH value 10 minutes after parathyroidectomy. Calcium levels were measured at 3 weeks and 6 months postoperatively. Cure was defined as eucalcemia at 6 months after surgery. Statistical calculation was performed using analysis of variance and chi-square analyses.

Results

When comparing the negative and positive imaging groups, there were no differences in patient age (mean age: 58 y; range, 23-80 y vs 58 y; range, 12-92 y), sex (88% vs 78% women), preoperative mean calcium level ($11.0 \pm .8$ mg/dL vs $11.3 \pm .9$ mg/dL), and PTH levels (129 ± 60 pg/mL vs 167 ± 63 pg/mL).

Neck exploration was performed under local anesthesia in 79.5% of positive imaging patients and 72.1% of negative

Table 1

Approach, Unilateral, Bilateral
Surgical time, Mean no. of Pathology, Single or Multiple Hyperplastic Carcinoma
Cured, %

imaging patients. The rate of conversion to bilateral neck exploration (NS) (Table 1) was significantly lower in the positive imaging group (70.4%; $P = .001$) compared with the negative imaging group (48.4%; $P = .001$). The conversion rate to bilateral neck exploration was significantly lower in the positive imaging group (70.4%) compared with the negative imaging group (48.4%; $P = .001$). The conversion rate to bilateral neck exploration was significantly lower in the positive imaging group (70.4%) compared with the negative imaging group (48.4%; $P = .001$). The conversion rate to bilateral neck exploration was significantly lower in the positive imaging group (70.4%) compared with the negative imaging group (48.4%; $P = .001$).

Comments

In this study, we compared the outcomes of patients with positive and negative preoperative localization to determine the impact of successful localization on resource use and cure rate. The conversion rate to bilateral neck exploration was significantly lower in the positive imaging group (70.4%) compared with the negative imaging group (48.4%; $P = .001$). The conversion rate to bilateral neck exploration was significantly lower in the positive imaging group (70.4%) compared with the negative imaging group (48.4%; $P = .001$). The conversion rate to bilateral neck exploration was significantly lower in the positive imaging group (70.4%) compared with the negative imaging group (48.4%; $P = .001$).

Table 1 Surgical and outcome data for negative and positive imaging patients

	Negative imaging (n = 44)	Positive imaging (n = 373)	P value
Approach, %			
Unilateral	29.6	91.9	<.0001
Bilateral	70.4	8.1	<.0001
Surgical time, min	77.3 ± 52.5	48.4 ± 34.6	<.0001
Mean no. frozen sections	.9 ± 1.3	.2 ± .7	.0007
Pathology, %			
Single adenoma	72.1	93.0	<.0001
Multiple adenoma	20.9	4.6	<.0001
Hyperplasia	7.0	1.4	.01
Carcinoma	0	1.1	NS
Cured, %	87.1	96.0	.03

imaging patients ($P =$ not significant [NS]), with a similar rate of conversion to general anesthesia (3.5% vs 2.3%; $P =$ NS) (Table 1). Positive imaging patients were more likely to have a single adenoma (93.0% vs 72.1%; $P < .001$), and were less likely to require a bilateral exploration (8.1% vs 70.4%; $P < .001$; Table 1) when compared with negative imaging patients.

Negative imaging patients were more likely to have multigland disease (20.9% vs 4.6%; $P < .001$) and hyperplasia (7% vs 1.4%; $P < .01$). Negative imaging patients also required more frozen sections ($.9 \pm 1.3$ vs $.2 \pm .7$; $P < .001$) and had a longer duration of surgery (77.3 ± 52.5 min vs 48.4 ± 34.6 min; $P < .001$).

The cure rate was significantly higher in the positive imaging group (96.0% vs 87.1%; $P < .03$) with no difference in the incidence of complications (3.2% vs 2.3%; $P =$ NS). When comparing negative and positive imaging patients, there were no differences in the incidence of same-day discharge (80% vs 89%; $P =$ NS), mean 6-month calcium levels (9.5 ± 1.1 mg/dL vs $9.5 \pm .7$ mg/dL; $P =$ NS), or mean 6-month PTH levels (45 ± 24 pg/mL vs 66 ± 38 pg/mL; $P =$ NS).

Comments

In this study, we compared the outcomes of patients with positive preoperative localization with those with negative or discordant localization. This study and others have shown that PHPT patients with negative imaging often are more complex and difficult to treat.^{3,19} In this subset of patients, there was a higher incidence of multigland disease and a higher rate of persistent hyperparathyroidism. Thus, in most cases, patients with unsuccessful localization before surgery require bilateral neck exploration to find the offending gland(s).

Technetium-99m-sestamibi planar and SPECT scintigraphy is useful for surgical planning and provides 3-dimensional localization and estimation of gland size.^{9,20} The diagnosis of parathyroid tumors with Tc-99m-sestamibi scintigraphy is based on the difference in washout of radio-

activity between the thyroid gland and the parathyroid glands.⁹ The characteristic retention of Tc-99m sestamibi within the diseased parathyroid has been attributed to the high metabolic activity and mitochondria-rich oxyphil cell content of hypermetabolic parathyroid glands.⁹ However, any condition that interferes with radiotracer clearance will limit the effectiveness of the study, including medications that interfere with thyroid metabolism such as Levothyroxine.⁹ Parathyroid hyperplasia, multigland parathyroid disease, and concomitant thyroid and parathyroid disease can influence the accuracy of sestamibi scanning, and optimal handling of these problems still relies on the skill and experience of the endocrine surgeon.⁹

In a 2006 study by Carneiro-Pla et al.,⁷ patients with negative or incorrect sestamibi scans were shown to have a significant change in surgical management by using intraoperative PTH (IOPTH) monitoring. In patients with incorrect sestamibi scan results, IOPTH monitoring identified additional hypersecreting glands not visualized on sestamibi scanning. In addition, IOPTH monitoring allowed some negative scan patients to undergo targeted resection of an adenoma not seen on prior imaging. However, because sestamibi scans can miss up to 87% of patients with multigland disease, IOPTH monitoring routinely is not recommended for use in surgeries for PHPT (whether or not there is positive sestamibi localization preoperatively).^{7,21,22}

Our study also corroborated a 2005 study by Grady et al.²³ in which preoperative calcium and PTH levels did not differ between scan-negative and scan-positive patients. These investigators also concluded that surgical time was significantly different between scan-negative, scan-positive, and equivocal scan groups, with the longest duration of surgery occurring in scan-negative patients.²³ The volume of the excised gland was significantly larger in the positive scan group patients, thus these investigators concluded that as the volume of the gland increases, so does the likelihood of a successfully chosen minimally invasive surgical approach. A previous study from our institution studied the use of sestamibi scanning during bilateral neck exploration,

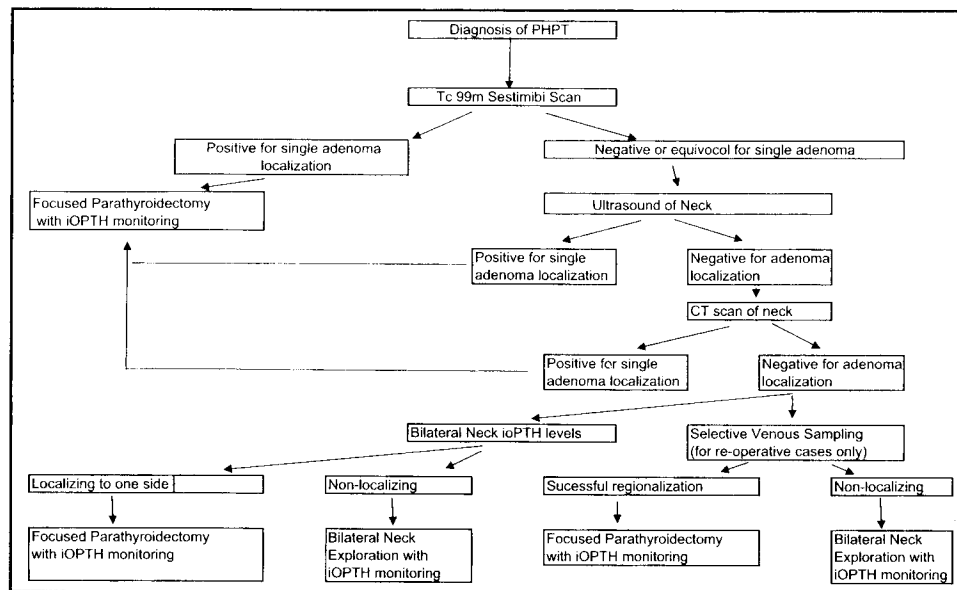


Figure 1 Surgical and diagnostic treatment algorithm for primary hyperparathyroidism.

concluding that scan-negative patients had a higher failure rate.²⁴

Ruda et al¹⁴ recently published an article on the cost effectiveness of treating PHPT and concluded that patients with negative sestamibi scans would benefit from additional preoperative imaging when compared with patients undergoing bilateral neck exploration without additional imaging studies. A preoperative strategy of obtaining additional localizing studies, such as ultrasound, computed tomography, or magnetic resonance imaging (MRI), was shown to be more cost effective given the longer surgical time, more complex intraoperative management, and higher failure rate in patients with negative sestamibi scanning.

A study from 2003 showed that a combined positive predictive value of SPECT scintigraphy and high-resolution ultrasonography was 99.2% as compared with 97% with SPECT alone.¹ Cost-effective ultrasonography shows a wide sensitivity range (36%–76%), which is related to the skill of the sonographer.⁹ In experienced hands, ultrasound performed with high-frequency probes and Doppler assessment is an excellent technique for imaging upper cervical parathyroid disease. However, ultrasound is of limited value in detecting mediastinal and tracheoesophageal lesions.⁹

The sensitivity of CT with intravenous contrast ranges from 45% to 80%, although the accuracy rate is highly dependent on the technique used as well as the experience of the radiologist in interpreting parathyroid CT images.^{9,25,26} In our experience with a radiologist dedicated to searching for abnormal parathyroid glands, CT scanning has been very helpful in detecting abnormal glands in the setting of negative sestamibi scans, but 2.5-mm slices need to be used to allow for an accurate evaluation of the neck.

MRI with 3-dimensional evaluation of the neck and upper chest has an excellent overall sensitivity of 78%.⁹ The sensitivity is higher in the mediastinum (almost 88%), a rate

equivalent to that of dual-phase Tc-99m-sestamibi scintigraphy.⁹ Thus, MRI also may be an alternative to preoperative imaging in the setting of negative sestamibi scans. However, MRI is significantly more expensive than other modalities, which brings up the question of cost effectiveness of this imaging modality versus intraoperative localization.

A proposed algorithm for patients with negative or equivocal preoperative localization is outlined in Fig. 1. If sestamibi scanning is negative, we recommend ultrasound as the next imaging modality before neck exploration. If ultrasound imaging is not helpful in parathyroid localization, then CT scan of the neck with 2.5-mm slices should be considered. An alternative option before conducting a bilateral neck exploration is to measure selective PTH levels from each internal jugular vein in the operating room. If a significant difference exists in the levels, a focused parathyroidectomy can be initiated on the side with the higher PTH level. Should iOPHT levels decrease appropriately after excision of an adenoma, the surgery can be concluded safely. Some clinicians have shown this approach to be efficacious, but we have found selective internal jugular venous intraoperative PTH measurements to be of limited utility.²⁷ For patients with persistent or recurrent hyperparathyroidism, selective venous sampling can be helpful in determining which parathyroid basin to explore (right neck vs left neck vs mediastinum).²⁸

There were some limitations with the current study. First, the study was a retrospective review of a prospectively maintained clinical parathyroid registry. The retrospective nature of the analysis offers only a snapshot of a given patient's clinical picture. Because our center is a large, tertiary referral center, many patients underwent localizing studies at outside institutions, thereby making it impossible to standardize imaging techniques. Regarding sestamibi

scanning, there is that varies from i of the sestamibi sity, especially i was not possible fore. assumption formulated base tions, longer du patients with ne; In conclusion patients with pr outcome. Negati of multigland d institutional resc tive localization PHPT should be are more likely these more com

References

- Shabtai M, Be minimally inva and long term
- Goldstein RE. sive radioguid costs in the m 2000;231:732-
- Mihai R, Gle primary hyper and high-reso 150 patients.
- Rotstein L, Iri the era of loc
- Inabnet WB J tomy in the J Surg 2002;:
- Carling T, D roidectomy t anesthesia. A
- Carneiro-Pla geted parathy operative par 715–22.
- Kebebew E. multigland p ple and accu
- Nguyen BD. SPECT scin
- Rubello D, C intraoperativ hyperparath

scanning, there is a wide range of techniques and quality that varies from institution to institution. Some, but not all, of the sestamibi scans were repeated at Columbia University, especially if the ultrasound was negative. Finally, it was not possible to perform an actual cost analysis, therefore, assumptions of increased resource utilization were formulated based on an increased number of frozen sections, longer duration of surgery, and lower cure rate in patients with negative localization.

In conclusion, the results of preoperative localization for patients with primary hyperparathyroidism correlate with outcome. Negative imaging patients have a higher incidence of multigland disease, lower cure rate, and consume more institutional resources than patients with positive preoperative localization. Patients with negative imaging studies for PHPT should be referred to experienced surgical teams who are more likely to have a higher success rate of cure for these more complex patients.^{1,5,13,14}

References

1. Shabtai M, Ben-Haim M, Muntz Y, et al. 140 Consecutive cases of minimally invasive, radio-guided parathyroidectomy: lessons learned and long term results. *Surg Endosc* 2003;17:688-91.
2. Goldstein RE, Blevins L, Delbeke D, et al. Effect of minimally invasive radioguided parathyroidectomy on efficacy, length of stay, and costs in the management of primary hyperparathyroidism. *Ann Surg* 2000;231:732-42.
3. Mihai R, Gleeson F, Buley ID, et al. Negative imaging studies for primary hyperparathyroidism are unavoidable: correlation of sestamibi and high-resolution ultrasound scanning with histological analysis in 150 patients. *World J Surg* 2006;30:697-704.
4. Rotstein L, Irish J, Gullane P, et al. Reoperative parathyroidectomy in the era of localization technology. *Head Neck* 1998;20:535-9.
5. Inabnet WB III, Dakin GF, Haber RS, et al. Targeted parathyroidectomy in the era of intraoperative parathormone monitoring. *World J Surg* 2002;26:921-5.
6. Carling T, Donovan P, Rinder C, et al. Minimally invasive parathyroidectomy using cervical block: reasons for conversion to general anesthesia. *Arch Surg* 2006;141:401-4.
7. Carneiro-Pla DM, Solorzano CC, Irvin GL III. Consequences of targeted parathyroidectomy guided by localization studies without intraoperative parathyroid hormone monitoring. *J Am Coll Surg* 2006;202:715-22.
8. Kebebew E, Hwang J, Reiff E, et al. Predictors of single-gland vs multigland parathyroid disease in primary hyperparathyroidism: a simple and accurate scoring model. *Arch Surg* 2006;141:777-82.
9. Nguyen BD. Parathyroid imaging with Tc-99m sestamibi planar and SPECT scintigraphy. *Radiographics* 1999;19:601-14.
10. Rubello D, Casara D, Shapiro D. Recent advances in preoperative and intraoperative nuclear medicine procedures in patients with primary hyperparathyroidism. *Panminerva Med* 2002;44:99-105.

11. Miccoli P, Monchik JM. Minimally invasive parathyroid surgery. *Surg Endosc* 2000;14:987-90.
12. Shen W, Sabanci U, Morita ET, et al. Sestamibi scanning is inadequate for directing unilateral neck exploration for first-time parathyroidectomy. *Arch Surg* 1997;132:969-76.
13. Kountakis SE, Maillard AJ. Parathyroid adenomas: is bilateral neck exploration necessary? *Am J Otolaryngol* 1999;20:396-9.
14. Ruda JM, Stack BC Jr, Hollenbeak CS. The cost-effectiveness of additional pre-operative ultrasonography or sestamibi-SPECT in patients with primary hyperparathyroidism and negative findings on sestamibi scans. *Arch Otolaryngol Head Neck Surg* 2006;132:46-53.
15. National Institutes of Health. Conference: diagnosis and management of asymptomatic primary hyperparathyroidism: consensus development conference statement. *Ann Intern Med* 1991;114:593-7.
16. Bilezikian JP, Potts JT Jr, Fuleihan Gel H, et al. Summary statement from a workshop on asymptomatic primary hyperparathyroidism: a perspective for the 21st century. *J Clin Endocrinol Metab* 2002;87:5353-61.
17. Wei JP, Burke GJ. Cost utility of routine imaging with Tc-99m-sestamibi in primary hyperparathyroidism before initial surgery. *Am Surg* 1997;63:1097-100.
18. Civelek AC, Ozalp E, Donovan P, et al. Prospective evaluation of delayed technetium-99m sestamibi SPECT scintigraphy for preoperative localization of primary hyperparathyroidism. *Surgery* 2002;131:149-57.
19. Westreich RW, Brandwein M, Mechanick JI, et al. Preoperative parathyroid localization: correlating false-negative technetium 99m sestamibi scans with parathyroid disease. *Laryngoscope* 2003;113:567-72.
20. Melton GB, Somervell H, Friedman KP, et al. Interpretation of ^{99m}Tc sestamibi parathyroid SPECT scan is improved when read by the surgeon and nuclear medicine physician together. *Nucl Med Commun* 2005;26:633-8.
21. Westerdahl J, Bergenfelz A. Sestamibi scan-directed parathyroid surgery: potentially high failure rate without measurement of intraoperative parathyroid hormone. *World J Surg* 2004;28:1132-8.
22. Bergson EJ, Szynter LA, Dubner S, et al. Sestamibi scans and intraoperative parathyroid hormone measurement in the treatment of primary hyperparathyroidism. *Arch Otolaryngol Head Neck Surg* 2004;130:87-91.
23. Grady JA, Bumpous JM, Fleming MM, et al. Advantages of a targeted approach in minimally invasive radioguided parathyroidectomy surgery for primary hyperparathyroidism. *Laryngoscope* 2006;116:431-5.
24. Allendorf J, Kim L, Chabot J, et al. The impact of sestamibi scanning on the outcome of parathyroid surgery. *J Clin Endocrinol Metab* 2003;88:3015-8.
25. Krebs FJ III, Archer CR, Awwad EE, et al. Preoperative computerized tomographic imaging in hyperparathyroidism. *Otolaryngol Head Neck Surg* 1987;97:351-5.
26. Rodgers SE, Hunter GJ, Hamberg LE, et al. Improved preoperative planning for directed parathyroidectomy with 4-dimensional computed tomography. *Surgery* 2006;140:932-41.
27. Lee LS, Canter RJ, Fraker DL. Intraoperative jugular venous sampling AIDS detection of an undescended parathyroid adenoma. *World J Surg* 2006;30:620-3.
28. Reidel MA, Schilling T, Graf S, et al. Localization of hyperfunctioning parathyroid glands by selective venous sampling in reoperation for primary or secondary hyperparathyroidism. *Surgery* 2006;140:907-13.